

CASE REPORT

Broken File Retrieval: Puzzle in Endodontics

¹Anil K Tomer, ²Sagarika Muni, ³Gaurav Bharadwaj, ⁴Nidhi Malik

ABSTRACT

The most common endodontic mishap that eventually occurs during any root canal therapy is the separation of instrument inside the canal. The separated instrument influences the final outcome and prognosis of the root canal therapy. It hinders the cleaning and shaping procedures as well as the irrigation of the canal portion apical to the level of obstruction. When an attempt to bypass such a fragment becomes difficult, it is advised to retrieve it by mechanical devices. This clinical case report describes the usage of three different techniques for retrieval of separated instrument.

Keywords: Braiding technique, Instrument retrieval, Instrument separation.

How to cite this article: Tomer AK, Muni S, Bharadwaj G, Malik N. Broken File Retrieval: Puzzle in Endodontics. *Int J Oral Care Res* 2016;4(1):75-78.

Source of support: Department of Conservative Dentistry and Endodontics, DJ College of Dental Science and Research Centre, Modinagar, Uttar Pradesh, India.

Conflict of interest: None

INTRODUCTION

File separation inside the root canal has become a common error in endodontics. The separated instrument, particularly a broken file, leads to the root canal obstruction and prevents thorough cleaning and shaping procedures. There can be continuous pain or discomfort in the involved tooth if the broken instrument is not removed or bypassed.¹

There are various reasons for instrument separation inside the canal, such as over-instrumentation, improper filing techniques, increased speed with rotary instrument, loss of tactile sensation, anatomical variations like curved canals, and accessory canals.² When instrument separation occurs, the clinician has the choice of (1) leaving the instrument in the canal, (2) bypassing and obturating the canal, or (3) retrieving the file segment either surgically or nonsurgically.

The success of file retrieval depends on the canal anatomy, metallurgy of the broken file segment, location of the fragment inside the canal, the plane in which the canal curves, the length of the separated fragment, and the diameter of the canal itself.³ There are various nonsurgical methods to retrieve a broken file segment, like the use of ultrasonic tips (ProUltra tips, Dentsply), Masserann Kit, Gates Gliden drills for coronal enlargement, etc.⁴

In this case report, the various treatment modalities are discussed when there was file separation inside the canal.

CASE REPORTS

Case 1

A 35-year-old male patient reported in the postgraduate clinic of the Department of Conservative Dentistry and Endodontics of our institute with the chief complaint of pain with relation to lower back teeth. The patient gave a history of root canal treatment in the lower back teeth at a private clinic 3 years back. He was experiencing pain in the same teeth since 3 to 4 months.

Clinical examination revealed that there was no associated swelling in relation to the involved teeth. Both teeth were tender on percussion. The surrounding gingival tissue appeared inflamed, but the pocked depths were within the normal limits. An attempt to retrieve this file was made using the needle of an 8 ml syringe. On the contrary, the back of the needle hub was attached to a suction device. This system created a backward pressure inside the tube and made the file tip to be pulled upward (Figs 1 to 4).

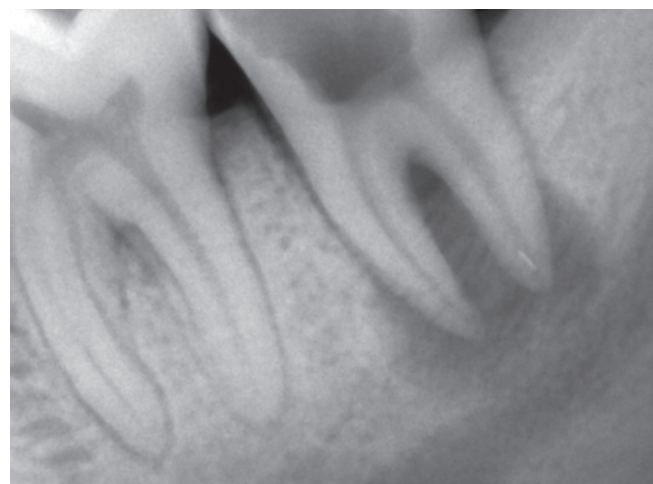

Fig. 1: Preoperative radiograph (Case 1)

¹Professor and Head, ²⁻⁴Postgraduate Student

¹⁻⁴Department of Conservative Dentistry and Endodontics, DJ College of Dental Sciences and Research, Modinagar, Uttar Pradesh, India

Corresponding Author: Sagarika Muni, Postgraduate Student Department of Conservative Dentistry and Endodontics, DJ College of Dental Sciences and Research, Modinagar Ghaziabad, Uttar Pradesh, India, Phone: +919536876848 e-mail: muni.sagarika@gmail.com

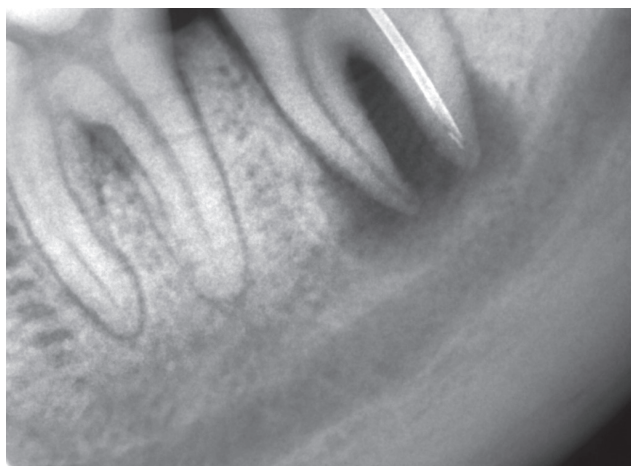


Fig. 2: Tip of a needle was approached toward the file

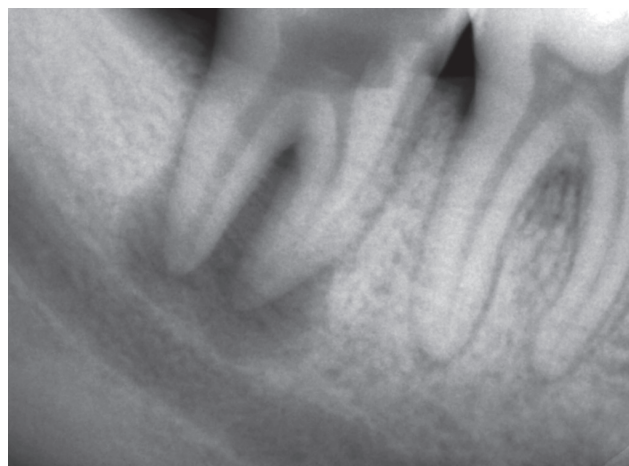

Fig. 3: Separated file tip retrieved

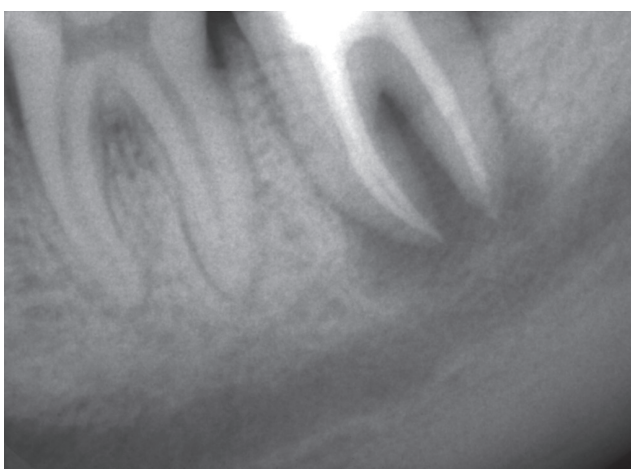

Fig. 4: Obturation radiograph (Case 1)

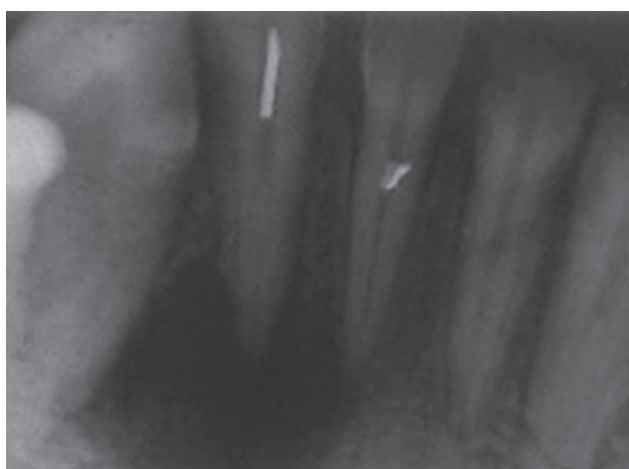


Fig. 5: Preoperative radiograph (Case 2)

Case 2

A 19-year-old male patient reported in the postgraduate clinic of the Department of Conservative Dentistry and Endodontics of our institute with the chief complaint of pain in relation to lower front teeth. The patient gave a history of initiation of root canal therapy in a private clinic, which ended with a separated file in the lower anterior region.

In this case, we used the “braiding file technique” to retrieve the file segment. The location of the broken file was coronal. Gates Gliden drills were used for coronal enlargement. Magnifying loupes were used for visibility of the file tip. Two H-files were inserted, one buccal and other lingual, and then the files were braided in the clockwise direction, in order to engage the file segment inside the canal. After giving a clockwise turn, they were pulled out of the canal. The file segment came out of the canal along with the H-files (Figs 5 to 9).

DISCUSSION

Retrieval of broken file segment has become a challenging part of root canal therapy. Various attempts can be made

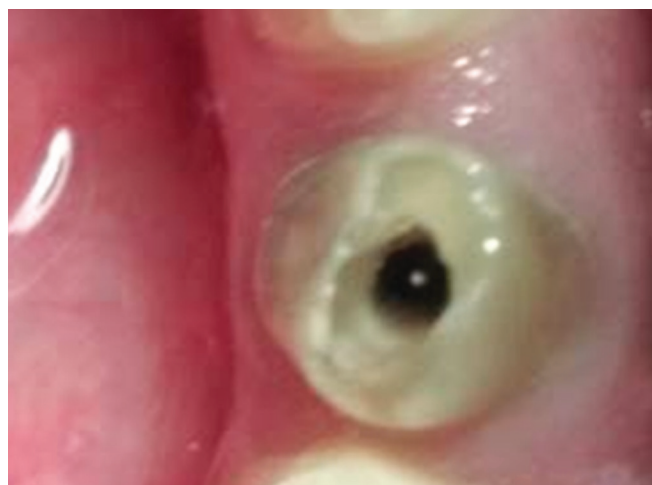

Fig. 6: File tip seen through magnifying loupes

to remove the broken file to increase the longevity of the treatment option.

Several methods are described to remove broken instruments or objects within root canals. The evaluation of fractured instrument removal systems and techniques, such as the Masserann Kit, Endo Extractor (Brasseler

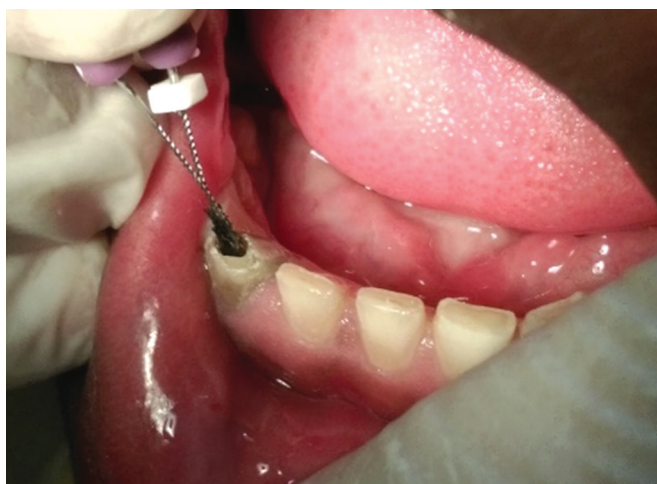

Fig. 7: H-file braiding technique

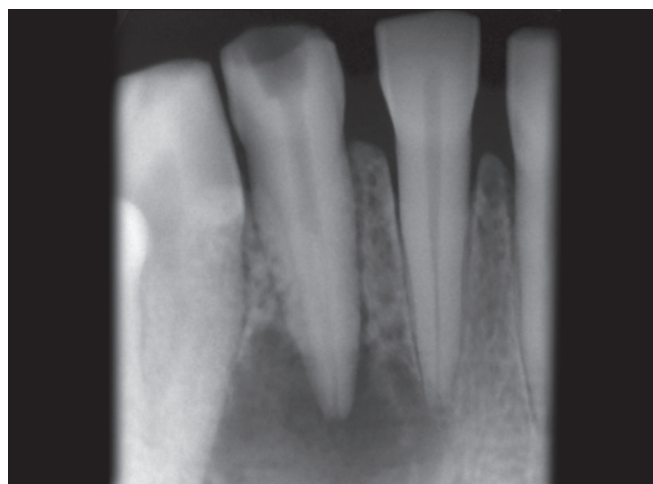


Fig. 8: File segment retrieved

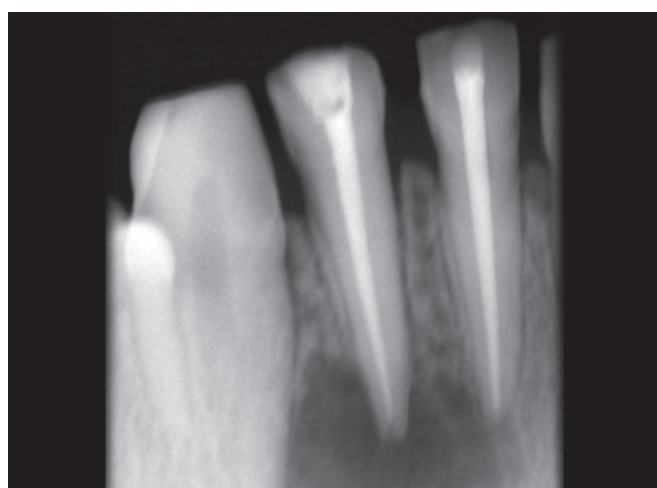


Fig. 9: Obturation radiograph (Case 2)

USA Inc.), wire loop technique, the Canal Finder System, and ultrasonic devices.⁵ The limitations of these devices include excessive removal of root canal dentin, ledging, perforation, limited application in narrow and curved roots, and extrusion of the fractured portion through the apex.

In the present case reports, we used a conservative approach to remove the file segment and to cause less harm to the tooth, by preserving the root canal dentin. In the first case, a suction device was used to pull up the file segment by creating a negative pressure. In the second case, an H-file braiding technique was used. One of the most important factors to be considered prior to instrument retrieval is to obtain a straight line access to the coronal end of the separated instrument by the use of modified Gates Gliden drills.⁶

However, this leads to removal of a considerable amount of radicular dentin and can cause iatrogenic damage like perforation.⁷ A close inspection of preoperative radiographs and knowledge of root anatomy is imperative before attempting the removal procedure in

any tooth to ascertain the relative amount of surrounding dentin and the risk of perforation.⁸ File removal generally results in ledge formation and therefore a possible stress concentration point. When the file is located in the middle or apical third of the root, removal procedure significantly reduces the root strength.⁹

CONCLUSION

This case report depicts the retrieval of broken file segment by two different methods: Use of suction device and braiding technique. These procedures were simple, cost-effective, and less harmful to the tooth. At last, this case followed a successful prognosis due to the perfect sealing of the root canal system.

ACKNOWLEDGMENT

I am thankful to Dr. Anil K Tomer, head who guided me in all the ways to solve these instrument retrieval cases.

REFERENCES

1. UnNisar SM, Kumar A, Iftekhhar H, Alam S. Retrieval of a separated nickel titanium instrument using a modified 18 guage needle and cyanoacrylate glue: a case report. *Restor Dent Endod* 2013 May;38(2):93-97.
2. Wadhawan R, Luthra K, Kaur Sidhu J, Solanki G. Are you ready to overpower the challenge of instrument separation in endodontics: a review. *Br J Mater Sci Technol* 2015;1(1):1-6.
3. Ruddle CJ. Broken instrument removal: the endodontic challenge. *Dent Today* 2002 Jul;21(7):70-72, 74, 76.
4. Shenoy A, Mandava P, Bolla N, Vemuri S. A novel technique for removal of broken instrument from root canal in mandibular second molar. *Indian J Dent Res* 2014 Jan-Feb;25(1): 107-110.
5. Chauhan R, Chandra A, Singh S. Retrieval of a separated instrument from the root canal followed by non-surgical healing of a large periapical lesion in maxillary incisors – a case report. *Endodontology* 2013;25(2):68-73.

6. Ruddle CJ. Nonsurgical retreatment: post and broken instrument retrieval. *J Endod* 2004 Dec;9(6):1-23.
7. Thirumalai AK, Sekar M, Mylswamy S. Retrieval of a separated instrument using Masserann technique. *J Conserv Dent* 2008 Jan-Mar;11(1):42-45.
8. Kunhappan S, Kunhappan N, Patil S, Agrawal P. Retrieval of separated instrument with instrument removal system. *J Int Clin Dent Res Organ* 2012;4(1):21-24.
9. Cohen SJ, Glassman GD, Mounce R. Rips, strips and broken tips: handling the endodontic mishaps. *Oral Health* 2005 May;10-20.